Clinical practice guideline for the management of endometrial polyps - a Euro-Chinese consensus

Lan Zhu[1], Xinmiao Bao[1], Rudi Campo[2], Limin Feng[3], Evy Gillet[2], Xuemei Jia[4], Fabiola Nardelli[5], Luis Alonso Pacheco[6], Vasilios Tanos[7], Jiali Tong[1], Yue Wang[8], Xiang Xue[9], Brunella Zizolfi[5], Grigoris Grimbizis[10*], Attilio Di Spiezio Sardo[5*]

[1]Department of Obstetrics and Gynecology, National Clinical Research Center for Obstetric and Gynecological Diseases, Peking Union Medical College Hospital, Chinese Academy of Medical Sciences and Peking Union Medical College, Beijing 100730, China.
[2]Life Expert Centre, Schipvaartstraat 4, Leuven, Belgium.
[3]Department of Obstetrics and Gynaecology, Beijing Tiantan Hospital, Capital Medical University, Beijing, China.
[4]Department of Gynecology, Women's Hospital of Nanjing Medical University (Nanjing Women and Children's Healthcare Hospital), Nanjing 210004, China.
[5]Gynaecology and Obstetrics Unit, Department of Public Health, University of Naples Federico II, Naples, Italy.
[6]Obstetrics and Gynecology Department, Reproductive Surgery Unit, Hospital Quirón, Malaga, Spain.
[7]Department of Obstetrics and Gynecology, Aretaeio Hospital, Nicosia, Cyprus.
[8]Department of Ambulatory Surgery, Women's Hospital, School of Medicine, Zhejiang University, Hangzhou, People's Republic of China.
[9]Department of Obstetrics and Gynecology, The Second Affiliated Hospital of Xi'an Jiaotong University, No.157 of Xiwu Road, Xi'an, People's Republic of China.
[10]1st Department of Obstetrics and Gynecology, “Papageorgiou” Hospital, Aristotle University of Thessaloniki, Thessaloniki 54124, Greece
*corresponding authors

Introduction

Endometrial polyps are benign hyperplastic lesions of the endometrium resulting from localized overgrowth of glands and stroma, covered by epithelium and projecting above the surrounding endometrial surface (1). Histopathologically, endometrial polyps are characterised by asynchronous development of glands and stroma compared with the surrounding endometrium, as well as irregular arrangement and shape of the glands, stromal fibrosis and the presence of thick-walled vessels (2).

Endometrial polyps can be diagnosed across all age groups, from adolescence to post menopause, although their prevalence increases progressively with advancing age (3). Clinical manifestations vary across age groups, primarily presenting as abnormal uterine bleeding and infertility; however, a proportion of patients remain asymptomatic (4). Diagnosis involves screening for risk factors of endometrial polyps (5,6). Transvaginal ultrasonography serves as the first-line imaging tool (7), while hysteroscopy with directed biopsy and histopathologic confirmation constitutes the diagnostic gold standard (8).

The management of endometrial polyps should be individualised according to the patient's menopausal status, symptomatic presentation, desire for future fertility, and estimated risk of malignant transformation. The surgical management of endometrial polyps has evolved considerably over the years. Blind dilatation and curettage (D&C), once considered the standard treatment, has progressively been replaced by hysteroscopy, which allows direct visualization of the uterine cavity and targeted lesion removal under visual control. Technological advances, including the development of miniaturised hysteroscopes and operative instruments such as mechanical scissors, bipolar electrodes, and tissue removal systems, have further expanded the role of hysteroscopy, enabling the treatment of many endometrial polyps in an outpatient setting. This has fostered the development of the “see-and-treat” approach (9) in which diagnosis and treatment are performed during the same procedure, improving patient convenience while reducing costs and treatment delays.

Furthermore, long-term clinical surveillance is strongly recommended for all patients diagnosed with endometrial polyps to minimise the risk of recurrence and malignant transformation (10). Modifiable risk factors associated with malignancy should be promptly identified and addressed, and treatment strategies should be individualised according to the patient's fertility desires and the histologic features of the polyp.

Given the wide onset age range and variable impact of endometrial polyps across patient populations, individualised management strategies are essential. This evidence-based diagnostic and

treatment algorithm has been developed to standardise clinical practice for distinct patient subgroups. The pathway provides consensus-based guidance to gynaecologists, facilitating feasible and standardised clinical management of endometrial polyps.

Clinical Significance

Key questions

Q1. What is the clinical significance of endometrial polyps in premenopausal women and women seeking pregnancy?

Endometrial polyps (EPs) are common focal overgrowths of endometrial glands and stroma in women of reproductive age. They may be asymptomatic or present with abnormal uterine bleeding (AUB), infertility or adverse reproductive outcomes. Their clinical relevance depends on symptoms, size, number and location, associated endometrial pathology and reproductive plans (11,12). Although the mechanisms linking EPs to infertility are not fully established, proposed effects include mechanical interference with sperm transport, distortion of the uterine cavity, local inflammation and impaired endometrial receptivity and embryo–endometrial interaction (11,12) .

Whether all EPs should be removed before spontaneous conception remains uncertain. Small polyps, particularly those <10 mm, may regress spontaneously and can be managed expectantly in selected asymptomatic women (11,13). Conversely, hysteroscopic polypectomy is reasonable in women with AUB, larger or multiple polyps, cavity distortion or otherwise unexplained infertility. Observational evidence suggests improved pregnancy rates following polypectomy, but robust evidence demonstrating an increase in live birth after natural conception is lacking. Current British Fertility Society (BFS) guidance therefore recommends individualised management according to polyp characteristics, symptoms, age, infertility duration and cause, and reproductive history (11) .

The impact of EPs on assisted reproduction is similarly uncertain. Although local inflammation and altered receptivity may impair implantation, evidence specifically supporting routine removal of isolated, small asymptomatic polyps before IVF/ICSI remains inconsistent (11,12). A meta-analysis of randomised trials found that outpatient hysteroscopy before assisted reproductive treatment was associated with higher clinical pregnancy and live-birth rates, although heterogeneity prevented attribution of this benefit specifically to polypectomy (14). More recently, a retrospective cohort of 372 women with suspected EPs detected during ovarian stimulation found no adjusted difference in live birth between fresh embryo transfer and a freeze-all strategy followed by polypectomy; the findings mainly concerned small polyps (mean 10–11 mm) (15). The BFS guideline therefore

supports an individualised approach; for polyps >20 mm detected during ovarian stimulation, elective embryo cryopreservation followed by polypectomy and frozen embryo transfer may be considered (11).

In contrast, the strongest evidence for polypectomy is in women undergoing intrauterine insemination (IUI). In a randomised study of 215 women, hysteroscopic removal of EPs before IUI resulted in 64 pregnancies compared with 29 in controls (RR 2.1, 95% CI 1.5–2.9) (16). However, this trial assessed pregnancy rather than live birth, and 65% of pregnancies in the polypectomy group occurred before the first IUI cycle (16) .

In women with recurrent implantation failure, removal of an identified EP is frequently considered because of its potential effect on endometrial receptivity; however, evidence of improved live birth remains limited (11,17) . Similarly, current evidence does not establish EPs as an independent cause of recurrent pregnancy loss or demonstrate that polypectomy reduces miscarriage rates (11,18). A recent cohort study detected at least one EP by three-dimensional transvaginal ultrasound in 4% of 442 women with unexplained recurrent pregnancy loss, but the absence of a control group and hysteroscopic confirmation precludes causal inference (18) .

Most EPs in premenopausal women are benign, although premalignant or malignant pathology can occur, particularly in women with AUB and metabolic or clinical risk factors (6,19). In a recent meta-analysis of 11,204 women with histologically confirmed EPs, malignant pathology was identified in 2.75%, while menopausal women had significantly higher odds of premalignant or malignant pathology than non-menopausal women (OR 5.63, 95% CI 3.87–8.20) (6). This pooled prevalence should not be extrapolated to all reproductive-age women; a separate meta-analysis reported malignant pathology in 1.12% of premenopausal polyps (19). Histological assessment is therefore appropriate when clinical or hysteroscopic findings are suspicious.

When treatment is indicated in women wishing to preserve fertility, hysteroscopic polypectomy should achieve complete excision while minimising endometrial trauma. Direct visualisation permits targeted removal and avoids the unnecessary endometrial injury associated with blind curettage (11,20). Mechanical hysteroscopic tissue-removal systems may be particularly attractive in this setting because they permit targeted excision without thermal injury, and the BFS guideline favours their use over bipolar electrosurgery when appropriate (11,21).

Key points

- *EPs may be associated with AUB and impaired reproductive outcomes.*
- *Functional polyps may regress spontaneously, and re-evaluation is recommended.*

Q2. What is the clinical significance of endometrial polyps in postmenopausal women and their association with malignancy?

Endometrial polyps are common focal lesions of the endometrial cavity and are usually benign. Their clinical significance, however, changes substantially after menopause, particularly in women presenting with postmenopausal bleeding (PMB), in whom the risk of premalignant or malignant pathology is increased (6,19). Although most polyps remain benign, atypical hyperplasia or carcinoma may arise within the polyp or coexist in the surrounding endometrium (22).

PMB is the most important clinical presentation requiring investigation. Approximately 90% of women with endometrial cancer present with vaginal bleeding (23). A systematic review and meta-analysis including 35,345 women reported malignant pathology in 4.93% of postmenopausal polyps compared with 1.12% in premenopausal women; the risk was higher in women with bleeding than in asymptomatic women (5.14% vs 1.89%) (19). Increasing age, particularly >60 years, obesity, diabetes, hypertension and tamoxifen exposure may further increase the risk (24,25). However, associations with individual risk factors, particularly tamoxifen exposure, are not consistent across the studies (6,25). Polyp size alone is an inconsistent predictor of malignancy, although multiple polyps may be associated with increased risk (25,26).

Transvaginal ultrasound (TVUS) is the first-line imaging modality when an EP is suspected. Assessment should include the polyp and the surrounding endometrium, including its thickness and morphology. Endometrial thickness is greater in polyps harbouring premalignant or malignant pathology, although it should not be interpreted in isolation, particularly in women with PMB (4,6). Small asymptomatic polyps carry a substantially lower absolute risk and do not necessarily require routine removal; however, bleeding, advanced age, a thickened or irregular endometrium and other risk factors for endometrial carcinoma should lower the threshold for histological assessment (4). Hysteroscopy offers an important diagnostic and therapeutic advantage because it permits direct visualisation, targeted biopsy and complete removal of focal lesions during the same procedure. Blind endometrial sampling may miss focal pathology and cannot confirm complete removal of an identified polyp. A recent joint AAGL–ESGE–Global Community on Hysteroscopy guideline therefore recommends visually directed hysteroscopic biopsy or resection when a polyp is suspected in women investigated for abnormal uterine bleeding or PMB (20).

Histopathological assessment remains essential because imaging cannot reliably distinguish benign polyps from atypical hyperplasia or carcinoma. Importantly, malignant or atypical pathology may extend beyond the polyp. In the multicentre study, atypical hyperplasia or endometrial cancer was found in 2.2% of 1,436 hysteroscopically removed polyps, while concomitant atypical pathology in the non-polypoid endometrium was identified in 66.6% (14/21) of women with atypical polyps

subsequently undergoing hysterectomy (27). Endometrioid carcinoma is the most commonly associated malignancy, although serous carcinoma, clear-cell carcinoma and carcinosarcoma may also occur within polyps (22).

Recent evidence reinforces the importance of menopausal status in risk stratification. A systematic review and meta-analysis of 11,204 peri- and postmenopausal women aged over 45 with histologically reported malignant pathology in 2.75% and atypical hyperplasia in 1.8% of women with EP; menopausal women had significantly higher odds of premalignant or malignant pathology than non-menopausal women (OR 5.63, 95% CI 3.87–8.20) (6).

Key points

- *In post-menopausal women, most EPs are benign, but the risk of premalignant or malignant pathology increases, particularly in women with PMB.*
- *TVUS and histopathological assessment should be considered for both the polyp and the surrounding endometrium.*

Risk Factors

Most endometrial polyps are benign lesions (4). However, premalignant or malignant pathology may be identified in a proportion of cases, with reported rates up to ~5% (4,5). Recognition of risk factors associated with the development of endometrial polyps and with an increased risk of premalignant or malignant pathology within endometrial polyps is important for patient counselling, risk stratification, diagnostic assessment, and clinical management.

Key questions

Q1: What risk factors are associated with the development of endometrial polyps?

The cause of endometrial polyps is unclear. The risk factors that contribute to the occurrence and malignancy of endometrial polyps overlap to some extent. Risk factors for the development of endometrial polyps can be grouped into advancing age, metabolic/endocrine factors, hormonal factors, inflammatory factors, and gynaecological comorbidities (4). Increasing age is a well-established risk factor for the presentation of an endometrial polyp, and they are more common in women in their 40s and 50s (28). Metabolic disorders, including obesity, hypertension, insulin resistance, and diabetes mellitus, have been associated with an increased prevalence of endometrial polyps (29). Hormonal factors include the use of tamoxifen (30) and estrogen-only menopausal hormone therapy. Patients receiving tamoxifen therapy are at specific risk for the development of endometrial polyps. It has been reported in the literature that the risk of endometrial polyps increases

by two to three times (28). The formation of endometrial polyps may also be caused by systemic inflammation and local chronic inflammation of the endometrium (31,32). Endometrial polyps may coexist with other estrogen-dependent gynaecological disorders, including endometriosis, uterine fibroids, and adenomyosis (33).

Key points

- *Ageing, hypertension, obesity, diabetes and use of tamoxifen are recognised risk factors for the development of endometrial polyps.*
- *Inflammatory factors and estrogen-related disorders have been associated with the development of endometrial polyps.*

Q2 What are the risk factors for premalignant or malignant pathology in endometrial polyps?

The risk of premalignant or malignant pathology within an endometrial polyp varies according to menopausal status and clinical presentation. It is known that the risk of malignancy is slightly lower in premenopausal and asymptomatic patients (24,34).

Increasing age, particularly age over 60 years (25,35), postmenopausal status (6,36) and abnormal uterine bleeding, especially postmenopausal bleeding (6,35) are consistently associated with an increased prevalence of premalignant or malignant pathology within endometrial polyps. Recognised risk factors include obesity, diabetes and hypertension. Other risk factors with less reliable associations to increased incidence of precancerous or malignant lesions include polyp size, particularly any specific size threshold (3,4,37). Tamoxifen treatment is associated with an increased risk of premalignant or malignant pathology in endometrial polyps (25). The relationship between the polyp size and the risk of malignancy remains controversial; it needs to be comprehensively analysed in combination with other factors (25,38).

Endometrial polyps can be associated with an increased risk of malignancy within subgroups of patients. Nulliparity was an independent risk factor for premalignant and malignant polyps (36). Previous studies have shown that parity has a protective effect against endometrial cancer. During pregnancy and childbirth, the predominance of progesterone may reduce cell proliferation, thereby lowering the risk of developing endometrial cancer (39). PCOS, which is frequently associated with chronic anovulation and prolonged unopposed estrogen exposure, has been associated with an increased risk of premalignant or malignant pathology within endometrial polyps. A retrospective study of 4236 premenopausal women showed that the risk of premalignant and malignant polyps in patients with PCOS was 2.75 (95% CI 1.02-3.45) times higher than that in non-PCOS patients (40). Another retrospective study showed that the proportion of pre-malignant and malignant histological

abnormalities in premenopausal women with polycystic ovary syndrome is significantly higher than in women without the syndrome (41). Furthermore, women with hereditary cancer syndromes associated with endometrial carcinoma (e.g., Lynch syndrome) warrant particular attention when endometrial polyps are identified (42,43).

Key points

- *Abnormal uterine bleeding, postmenopausal status, age over 60 years, nulliparity, diabetes mellitus, obesity, PCOS, unopposed estrogen and tamoxifen use are high-risk factors for malignancy of endometrial polyps.*
- *Polyp size, as an independent risk factor for malignancy of endometrial polyps, remains uncertain and requires comprehensive analysis combined with other high-risk factors.*

Diagnosis

Transvaginal ultrasound is the first-line imaging modality for suspected endometrial polyps. Hysteroscopy represents the gold-standard technique for direct assessment of endometrial polyps, whereas histopathologic examination is required for definitive diagnosis (4,5).

Key questions

Q1 What is the role of transvaginal ultrasound in the diagnosis of endometrial polyps?

Two-dimensional transvaginal ultrasound should be considered the first-line imaging investigation when an endometrial polyp is suspected (4,5). When transvaginal ultrasound is not feasible, such as in women who are not sexually active or in the presence of anatomical limitations to vaginal access, transrectal ultrasound may be considered as an alternative approach (4).

A typical endometrial polyp appears as a focal intracavitary lesion, usually homogeneous and hyperechogenic, with well-defined margins (Figure 1). Characteristic sonographic features include regular cystic spaces, a bright edge at the lesion–endometrium interface, and a single dominant feeding vessel on colour or power Doppler (44–46).

The single feeding vessel sign (Figure 2) is one of the most characteristic Doppler findings of an endometrial polyp and represents a dominant vascular pedicle entering the lesion from the surrounding endometrium. However, its absence does not exclude the diagnosis (44–46).

Small regular cystic spaces may be observed within the lesion and correspond to cystically dilated endometrial glands. A bright edge (Figure 3) may also be visible around the lesion, particularly when the polyp is contrasted by intracavitary fluid, helping to delineate the polyp from the

surrounding endometrium. These findings should be interpreted together rather than individually, since no single ultrasound feature is pathognomonic (44–46).

Features such as heterogeneous echogenicity, irregular margins, disruption of the endometrial–myometrial junction, multiple or densely branching vessels, or abnormal surrounding endometrium are less typical of a conventional benign polyp and should prompt consideration of alternative or associated endometrial pathology (44–47).

Figure 1. Typical ultrasonographic appearance of an endometrial polyp on transvaginal ultrasound, presenting as a well-defined focal echogenic lesion within the endometrial cavity.

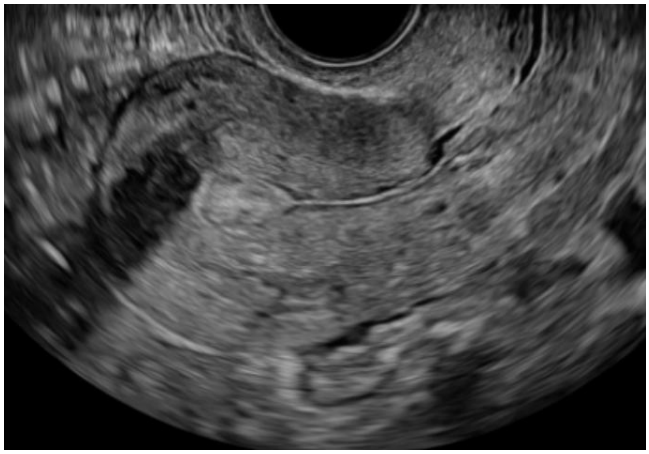

Figure 2. Feeding vessel sign. Colour Doppler ultrasound demonstrating a single dominant vessel entering the endometrial polyp.

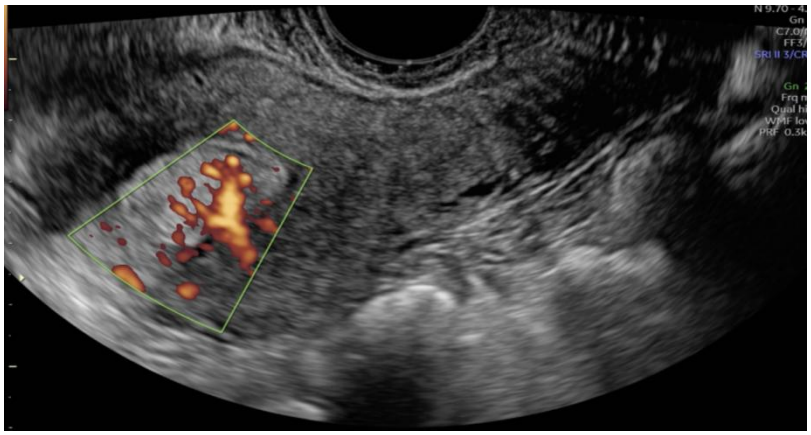

Figure 3. Bright edge sign. A hyperechoic rim surrounding the endometrial polyp, particularly visible when the lesion is contrasted by intracavitary fluid, helping to delineate it from the surrounding endometrium.

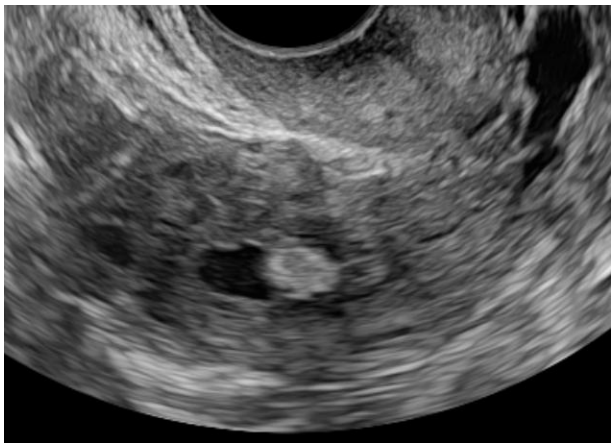

Key points

- *TVUS is the first-line imaging modality for suspected endometrial polyps.*
- *Typical sonographic features include a focal homogeneous hyperechogenic lesion, regular cystic spaces, a bright edge, or a single dominant feeding vessel.*
- *Irregular morphology or atypical vascularisation should raise suspicion for pre-malignant or malignant endometrial pathology.*

Q2. What is the role of contrast sonography and other imaging modalities in the diagnosis of endometrial polyps?

Contrast sonography creates negative contrast within the uterine cavity and improves delineation of focal intracavitary abnormalities. These techniques are particularly useful when conventional TVUS is inconclusive or when differentiation between focal and diffuse endometrial pathology is required (4,5,48).

In a systematic review and meta-analysis evaluating women with abnormal uterine bleeding, pooled sensitivity and specificity for the diagnosis of endometrial polyps were 0.87 and 0.86 for contrast sonography, compared with 0.62 and 0.73 for TVUS and 0.92 and 0.85 for hysteroscopy, respectively (48). Although the included studies were heterogeneous, these data support the use of intracavitary contrast sonography as a second-line imaging modality when standard TVUS does not clearly characterise the uterine cavity.

Contrast sonography is an imaging procedure and cannot provide histopathological confirmation. Therefore, it should not replace hysteroscopic tissue assessment when definitive histological diagnosis is required (4,5).

Three-dimensional ultrasound may be considered as an adjunctive imaging technique when conventional TVUS does not clearly characterise the uterine cavity (4,5). Computed tomography and magnetic resonance imaging have no routine role in the diagnosis or characterisation of endometrial polyps (4).

Key points

- *Contrast sonography should be considered when TVUS is inconclusive or when focal and diffuse endometrial abnormalities need to be distinguished.*
- *Three-dimensional ultrasound may be used as an adjunct but should not replace contrast sonography, hysteroscopy, or histopathology.*
- *CT and MRI should not be routinely used for the primary diagnosis of endometrial polyps.*

Q3 What is the role of hysteroscopy in the diagnosis of endometrial polyps?

Hysteroscopy is the reference standard for direct assessment of the uterine cavity. It allows direct visualisation and morphological characterisation of suspected endometrial polyps and enables targeted tissue acquisition when histological confirmation is required (4,5) .

A typical endometrial polyp appears as a well-demarcated focal intracavitary protrusion (Figure 4). Lesions may be pedunculated or sessile and usually have a smooth, regular surface (4,5). Hysteroscopic findings such as increased or irregular vascularity, surface irregularity, ulceration, necrotic area, and abnormal bleeding should raise concern for atypical or malignant pathology (49–51). Increased polyp vascularity in particular has been associated with premalignant or malignant histopathology (51).

Nevertheless, hysteroscopic appearance alone cannot reliably exclude atypia or malignancy. Therefore, histopathological evaluation remains necessary when tissue diagnosis is required (4,5,49–51).

Blind endometrial sampling and blind dilatation and curettage should not be used as the sole diagnostic method for suspected focal endometrial polyps when hysteroscopic evaluation is available (4,5,20,52,53). Blind techniques may miss focal lesions and provide inadequate representation of the lesion itself (20, 52,53). Evidence comparing hysteroscopically directed biopsy with blind sampling has shown improved sample adequacy and lower diagnostic failure when tissue is obtained under direct visualisation (53).

Figure 4. Different hysteroscopic appearances of endometrial polyps, illustrating the variability in size, shape, surface, vascular pattern, and site of implantation.

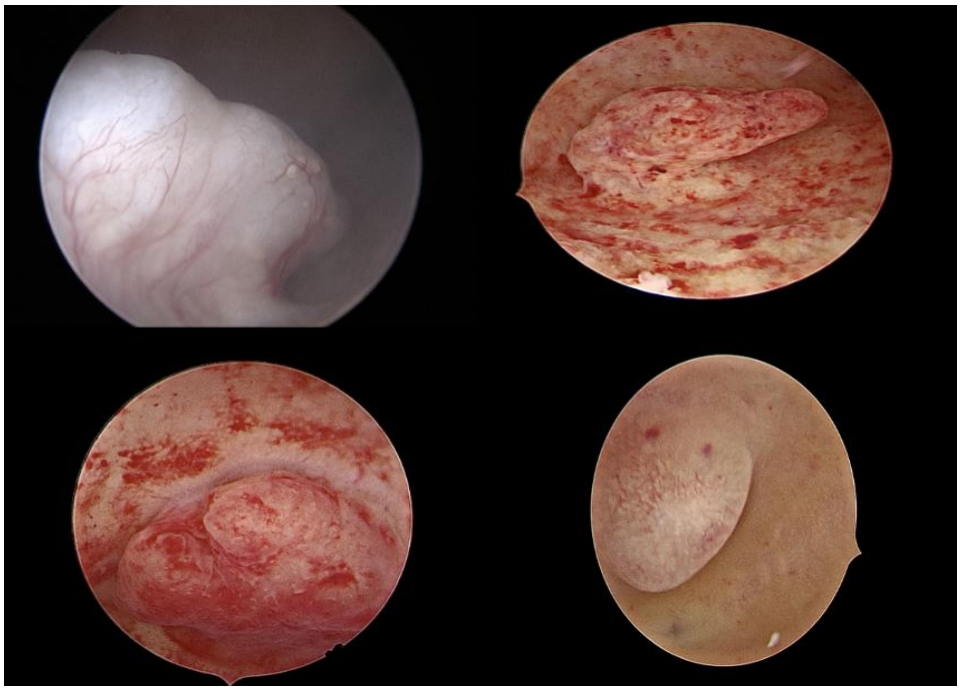

Key points

- *Hysteroscopy is the reference standard for direct visualisation and morphological assessment of suspected endometrial polyps.*
- *A benign hysteroscopic appearance cannot exclude atypia or malignancy.*
- *Blind biopsy or dilatation and curettage is not recommended to be used as the sole diagnostic method for suspected focal polyps.*

Q4. What is the role of histopathology in the diagnosis of endometrial polyps?

Histopathological examination represents the definitive method for confirming the diagnosis of an endometrial polyp and for identifying associated premalignant or malignant endometrial pathology (4,5).

Histologically, an endometrial polyp is characterised by a polypoid proliferation of endometrial glands and stroma, typically containing a fibrous or collagenized stromal component and characteristic thick-walled blood vessels. The glands may be irregularly distributed or cystically dilated (5,54). Different histological patterns may be encountered within otherwise benign endometrial polyps, including functional, hyperplastic and atrophic changes (54,55). Although these patterns may be described histologically, their subclassification has no established clinical or prognostic implications (55).

From a clinical perspective, histopathological assessment should primarily confirm the presence of an endometrial polyp and identify any associated endometrial hyperplasia without atypia, endometrial intraepithelial neoplasia (EIN)/atypical hyperplasia, or carcinoma (4–6,25).

Atypical polypoid adenomyoma (APA) represents a distinct pathological entity characterised by atypical endometrial glands, often with squamous nodules, within a myofibromatous stroma, and should be distinguished from conventional endometrial polyps and other polypoid endometrial lesions (56).

Key points

- *Histopathological examination is the definitive method for confirming the diagnosis of an endometrial polyp.*
- *Characteristic histological features include endometrial glands within a fibrous/collagenized stroma containing thick-walled vessels.*
- *Histological assessment should identify any associated hyperplasia, EIN/atypical hyperplasia or carcinoma.*

Management

Management of endometrial polyps should be individualised according to the patient's clinical characteristics, symptoms, reproductive goals, menopausal status, risk factors for endometrial malignancy, and polyp-related features (3–5). Although hysteroscopic polypectomy remains the definitive treatment and provides histological diagnosis, not all endometrial polyps necessarily require immediate surgical intervention (4,5). In selected patients, expectant management may be appropriate, while medical treatment may have a limited role in specific clinical settings (5).

Therefore, the choice between expectant, medical, and surgical management should balance the probability of spontaneous regression, persistence or recurrence of the lesion, the presence and severity of symptoms, the potential impact on fertility, and the risk of premalignant or malignant pathology (3–5).

Expectant management

Expectant management may represent an appropriate option for selected women with endometrial polyps because most polyps are benign and spontaneous regression can occur (4). The decision to adopt a conservative approach should balance the likelihood of spontaneous regression against the potential for persistence or symptom development and, more importantly, the individual risk of premalignant or malignant disease (4,5). Conservative management should not be selected on

lesion size alone. Symptoms, menopausal status, reproductive goals, polyp characteristics, and individual risk factors for premalignant or malignant disease should be considered together (4,5,57–60).

Key questions

Q1. Which patients with endometrial polyps are suitable for expectant management?

Expectant management can be considered in asymptomatic patients assessed to have a low risk of malignancy (4). Reviews and expert guidance similarly identify small, asymptomatic polyps, particularly in premenopausal women, as the group most considered for surveillance (5,57–60).

The natural-history evidence is mainly observational. Yuksel et al. reported spontaneous regression in 28 of 123 conservatively followed women (22.8%); regression was associated with age <45 years, premenopausal status, polyp size <2 cm, and abnormal uterine bleeding, while all postmenopausal women in that cohort had persistent polyps (61). In a larger retrospective cohort of 1006 asymptomatic women managed either expectantly or with hormonal medication, Mak et al. observed an overall regression rate of 33.5%; regression occurred in 8.9% after expectant management and 24.6% after hormonal treatment, whereas age ≤50 years was associated with higher regression rates (62). These studies support the possibility of regression but do not establish a single size or age threshold that should determine management.

More recently, Silva et al. followed 298 asymptomatic women with sonographically benign-appearing polyps and reported complete spontaneous regression in 24/298 (8.05%; 95% CI 5.2–11.9), with numerically higher regression in premenopausal than postmenopausal women (14.5% vs 6.4%). Abnormal uterine bleeding developed during follow-up in 8.7%, and one malignant lesion was identified among excised specimens (63). This supports structured ultrasound surveillance in carefully selected asymptomatic women but also confirms that surveillance requires predefined triggers for reassessment.

The commonly quoted <10 mm threshold is supported mainly by review synthesis rather than by all primary natural-history studies. Several reviews state that smaller polyps, particularly those <10 mm, are more likely to regress (4,5,57–59) whereas Yuksel et al. identified <2 cm as the size category associated with regression (61).

Accordingly, expectant management should not be considered solely based on polyp size. Clinical symptoms, menopausal status and individual risk factors for endometrial malignancy should also be considered. When expectant management is chosen, clinical and/or ultrasound reassessment may be considered. Follow-up should therefore be individualised according to the patient's clinical and sonographic risk profile. The development of abnormal uterine bleeding during follow-up,

persistence or enlargement of the lesion, or the emergence of additional risk factors should prompt clinical reassessment and consideration of hysteroscopic evaluation

Key points

- *Expectant management can be considered in asymptomatic women at low risk of malignancy; clinical and/or ultrasound reassessment at 6–12 months may be considered.*
- *Spontaneous regression is documented, but reported rates vary markedly across cohorts; younger age, premenopausal status, and smaller polyp size favour regression, but no single age or size cut-off has been identified.*
- *Surveillance should include reassessment if abnormal uterine bleeding develops, the lesion enlarges or persists, or the patient's malignancy-risk profile changes.*

Q2. How should asymptomatic endometrial polyps be managed in women desiring pregnancy?

Endometrial polyps are a potentially reversible intrauterine factor in women with subfertility, but the magnitude of their reproductive effect and the benefit of removal differ according to the reproductive pathway. Proposed mechanisms include mechanical interference with sperm transport or embryo implantation and changes in endometrial receptivity and local inflammation; these mechanisms are biologically plausible but do not by themselves establish a treatment effect (5, 60, 64–67). Given the potential reproductive impact of endometrial polyps and the availability of minimally invasive hysteroscopic treatment, expectant management should be considered selectively rather than as the preferred strategy in women actively seeking pregnancy.

For intrauterine insemination (IUI), an older systematic review identified one randomised study reporting higher pregnancy rates after polypectomy, making IUI the setting with the clearest historical signal of benefit (64). However, the 2014 Cochrane review found that the randomised trial contained internal inconsistencies that prevented extraction of an analysable dataset and concluded that no sound randomised evidence was available to establish the efficacy or safety of routine polypectomy in sub fertile women (68). Therefore, the evidence should be described as suggestive rather than definitive. Contemporary guidance nevertheless tends to favour or offer hysteroscopic resection in infertile women (4, 65–67). Accordingly, expectant management has a limited role in women undergoing IUI when an endometrial polyp has been identified.

For natural conception, evidence is predominantly observational and review based. Reviews generally report improved pregnancy after removal in selected infertile women, but robust randomised evidence for routine removal in every asymptomatic patient is lacking (64–68). Despite this limited certainty, hysteroscopic polypectomy may be favoured in women actively seeking

spontaneous conception, particularly when the polyp represents the only identified intrauterine abnormality, while expectant management may remain reasonable in selected cases after individualized counselling. The certainty of a live-birth benefit, however, remains limited.

For IVF/ICSI, the evidence is more heterogeneous. Afifi et al. reported no clear benefit in the retrospective assisted-conception studies available at that time and recommended individualised management when a polyp is diagnosed during controlled ovarian hyperstimulation (64) . The Cochrane review likewise found insufficient randomised evidence (68). More recent reviews continue to emphasise limited and heterogeneous comparative data (66,67). Importantly, a recent retrospective cohort study of 372 patients with a newly suspected polyp during IVF/ICSI stimulation found no significant difference in clinical pregnancy or live birth between proceeding with fresh embryo transfer and a freeze-all strategy followed by hysteroscopy; after adjustment, treatment strategy was not associated with live birth (15). These findings do not support mandatory cancellation of an ongoing IVF/ICSI cycle for every newly diagnosed asymptomatic polyp, but they should not be interpreted as evidence in favour of routine expectant management before initiation of ART.

Guideline wording is therefore stronger than the underlying randomised evidence in some settings. The 2024 Society of Obstetricians and Gynaecologists of Canada (SOGC) guideline recommends offering hysteroscopic resection to infertile patients with an endometrial polyp regardless of size, while also stating that, when a new polyp is diagnosed during IVF stimulation, cycle cancellation, freeze-all, and transfer should be discussed and that there is no evidence supporting mandatory cycle cancellation (4). This distinction should be retained in a consensus document rather than generalised into a single rule for all fertility pathways.

Key points

- *Expectant management has an unproven role in women with endometrial polyps actively seeking pregnancy and should be proposed only after individualised counselling.*
- *For natural conception, polypectomy may be considered; the evidence is mainly observational, but hysteroscopic polypectomy is generally favored, particularly when the polyp is the only identified intrauterine abnormality.*
- *Better reproductive outcome after polypectomy for patients undergoing IUI is expected, although strong evidence remains limited.*
- *For polypectomy before IVF/ICSI, evidence is more heterogeneous, but it still remains as a reasonable option.*

Q3. Is expectant management appropriate in asymptomatic postmenopausal women?

Expectant management is more controversial after menopause because malignancy risk is higher. In a systematic review and meta-analysis of 35,345 surgically removed polyps, malignant polyps were reported in 4.93% of postmenopausal versus 1.12% of premenopausal women; malignancy was also more frequent in symptomatic than asymptomatic women (5.14% vs 1.89%) (19). These data support menopausal status and bleeding status as major components of risk stratification.

The 2024 SOGC guideline on endometrial polyps recommends referral for further investigation and consideration of resection in patients who are menopausal, aged ≥60 years, have postmenopausal bleeding, or are taking tamoxifen (4). Therefore, postmenopausal bleeding associated with a polyp should not be presented as a routine expectant-management scenario. Timmermans et al. attempted a randomized comparison of immediate removal versus expectant management in women with postmenopausal bleeding, but the trial failed because of recruitment difficulties; the paper is important primarily because it demonstrates the lack of definitive randomised evidence rather than evidence of equivalence between strategies (69).

In asymptomatic postmenopausal women, routine ultrasound screening specifically for the detection of endometrial pathology is not recommended. However, when endometrial thickening or another endometrial abnormality is incidentally identified on ultrasound performed for another indication, endometrial thickness should not be interpreted in isolation, and sonographic morphology and vascular features should also be considered (46,70).

Current guidance uses different thresholds in the assessment of global endometrial thickening: the 2026 International Society of Ultrasound in Obstetrics & Gynaecology (ISUOG) Consensus Statement considers an endometrial thickness >4 mm as one of several sonographic alarm features rather than an isolated indication for invasive investigation (46), whereas the 2024 SOGC guideline recommends further assessment for global endometrial thickness >11 mm and/or suspicious sonographic features (70). Importantly, these thresholds refer primarily to global endometrial thickening and should not be directly applied to focal intracavitary lesions. When an endometrial polyp is identified, management should instead be guided by lesion morphology and vascular characteristics, symptoms, menopausal status, age, and other risk factors (4,46).

For asymptomatic postmenopausal women with a benign-appearing polyp, the available evidence permits a more individualised discussion. Previous evidence-based guidance recommended removal of asymptomatic postmenopausal polyps with a large diameter (>2 cm) or in women with known risk factors for endometrial carcinoma, whereas removal of smaller polyps (<2 cm) was not considered cost-effective (5). However, polyp size should not be considered an isolated criterion for management, as its association with malignancy has been inconsistent across studies (5,19). Silva et

al. included 236 postmenopausal women in structured surveillance and observed spontaneous regression in 6.36% (63). Reviews also describe observation as a possible option for carefully selected asymptomatic women, while emphasising that risk increases with age, menopause, bleeding, and other oncologic factors (5,19,57–60). Thus, conservative management may be considered only after explicit risk assessment and counselling about diagnostic uncertainty.

Ultrasound appearance cannot replace histology when malignancy or atypia is suspected (4). If atypia is actually identified within a polyp, the clinical pathway changes substantially: Rick et al., in a systematic review, estimated a pooled 5.6% risk of concurrent endometrial cancer in non-polypoid endometrium after diagnosis of atypia within a polyp (71). This estimate should not be extrapolated to an unbiopsied benign-appearing polyp, but it reinforces the importance of histological assessment when atypia is suspected.

Key points

- *Endometrial-thickness thresholds used for global endometrial thickening should not be directly applied to focal lesions such as endometrial polyps; morphology, vascular features and clinical risk factors should guide assessment.*
- *Expectant management of a benign-appearing polyp may be considered only in carefully selected asymptomatic postmenopausal women after individualised risk assessment and counselling.*
- *Postmenopausal bleeding or suspicious clinical or sonographic features should prompt further investigation rather than routine expectant management.*

Q4. What is the role of expectant management in women receiving tamoxifen?

Tamoxifen exposure is a distinct risk modifier. Reviews and expert series identify tamoxifen as a risk factor for endometrial polyp formation and as part of the clinical profile associated with endometrial pathology (4,57,58,60).

Routine ultrasound screening of asymptomatic women receiving tamoxifen is not recommended. The 2024 SOGC guideline on asymptomatic endometrial thickening specifically states that asymptomatic women on tamoxifen should not undergo routine/screening ultrasound (70). This position is reinforced by the 2026 ISUOG Consensus Statement, which states that routine endometrial ultrasound screening is not indicated in asymptomatic women receiving tamoxifen (46), and by ACOG, which notes the poor correlation between sonographic endometrial thickness and endometrial pathology in asymptomatic tamoxifen users (72).

Endometrial thickness should be interpreted with particular caution in tamoxifen users because treatment-related cystic and stromal changes may result in an apparently thickened

endometrium. Several thresholds have been evaluated in individual studies and previous guidance (73,74), but no single endometrial-thickness cut-off is universally validated for asymptomatic tamoxifen-treated women. Current guidance therefore emphasises that endometrial thickness should not be used in isolation to determine the need for further investigation (46,70,72).

The presence of abnormal vaginal bleeding is different and should override an isolated measurement of endometrial thickness. ACOG recommends investigation of any abnormal vaginal bleeding, bloody discharge, staining, or spotting in women taking tamoxifen (72). The 2026 ISUOG Consensus Statement likewise recommends ultrasonography as the first-line examination in women with abnormal uterine bleeding while receiving SERM therapy and uses sonographic morphology to triage subsequent testing (46). Thus, abnormal bleeding in a tamoxifen user warrants investigation irrespective of endometrial thickness.

More importantly for the management of endometrial polyps, the identification of a focal lesion should be distinguished from the assessment of global endometrial thickness. The 2024 SOGC polyp guideline recommends that patients taking tamoxifen who have an endometrial polyp be referred for further investigation and consideration of polyp resection (4). The 2026 ISUOG Consensus Statement recommends hysteroscopic removal when a focal endometrial lesion is associated with abnormal uterine bleeding and emphasises suspicious morphology and vascularity when deciding on sampling in women without bleeding (46).

Accordingly, routine screening of every asymptomatic tamoxifen user should be distinguished from management of a confirmed polyp. Once a polyp is identified, the evidence remains insufficient to support a general recommendation for expectant management, and there is no direct randomised comparison establishing the safety of surveillance of confirmed polyps in tamoxifen users. Expectant management should therefore be considered cautiously and selectively, with a lower threshold for hysteroscopic and histological assessment in postmenopausal women, in those with abnormal vaginal bleeding, and when additional oncologic risk factors or suspicious sonographic features are present (4,46,57,58,60,70,72) .

For recurrent polyps, a 2026 review identifies tamoxifen use among reported independent risk factors for recurrence and emphasises individualised management according to recurrence risk and clinical context (75). This evidence is indirect for the question of expectant versus surgical management but is relevant when repeated recurrence is being discussed.

Key points

- *Once an endometrial polyp is identified, expectant management has a limited role; hysteroscopic and histological assessment should be considered, particularly in the presence of*

postmenopausal status, abnormal bleeding, additional risk factors, or suspicious sonographic features.

Medical Treatment

Medical treatment is mainly used to distinguish whether a lesion is a functional endometrial polyp, to treat polyp-related abnormal uterine bleeding (AUB), and for long-term postoperative management to prevent polyp recurrence. Medical therapy is suitable in the following situations: presence of polyp-related clinical symptoms (such as AUB), attempts to reduce polyp size with medication, and in patients with contraindications to surgery or those who refuse surgical treatment.

Key questions

Q1: Is there a place for hormonal management?

Hormonal therapy is central to the medical management of endometrial polyps. Commonly used medications include combined oral contraceptives (COC) and progestins (second-half cycle progestins and LNG-IUS).

COC demonstrates a more significant clinical advantage in promoting polyp regression compared to the second-half cycle progestin regimen. COC has a strong regularity in its administration pattern and high patient compliance, providing sustained suppression of endometrial formation. While promoting polyp regression, COC can also improve AUB symptoms in premenopausal patients with endometrial polyps who have no contraindications. It should be taken cyclically according to the medication instructions, with a recommended evaluation of efficacy after using COC for 3 or more cycles. Second-half cycle progestin withdrawal treatment is equivalent to "medical curettage." Oral progestins, including dydrogesterone 10–20 mg/day, micronised progesterone 200–300 mg/day, and medroxyprogesterone acetate 10–20 mg/day, can be used cyclically after day 11th to 15th of the menstruation or of a withdrawal bleeding, for 10–14 days, for 3 consecutive cycles. Studies show that after 3 months of dydrogesterone treatment, the symptom improvement rate is 95.1%, and the ultrasound improvement rate is 55% (76). The LNG-IUS releases progestin locally within the uterine cavity, inhibiting endometrial growth and thus suppressing the growth of endometrial polyps, while significantly reducing menstrual flow. LNG-IUS can also be used to prevent polyp recurrence after hysteroscopic endometrial polypectomy. Compared to dydrogesterone or COC, patients with LNG-IUS placement post-surgery have a lower recurrence rate (77,78).

During medical treatment, follow-up and efficacy evaluation should be conducted, with TVS re-examination recommended every 3-6 months to dynamically monitor changes in endometrial

thickness and polyp size and morphology. Treatment regimens should be adjusted based on evaluation results: if there is a good response to medication (polyp reduction ≥50% or significant symptom improvement), the original regimen can be maintained; if efficacy is suboptimal, consider adjusting the medication dosage (e.g., increasing progestin dosage) or switching medication types (e.g., from oral progestins to COC); if polyps persist or symptoms do not improve after 6 months of standard medical treatment, reassessment of the necessity for surgical treatment is required to exclude the possibility of endometrial malignancy. The treatment strategy for endometrial polyps should be individualised based on the patient's age, symptom severity, fertility needs, and risk of malignancy. Regardless of the chosen strategy, regular follow-up, efficacy evaluation, and timely adjustment of the treatment plan are crucial to ensuring treatment success, improving patient quality of life, and preventing potential malignancy risks.

Key points

- *Hormonal management in case of suspected functional polyps commonly includes combined oral contraceptives (COC) and progestins (cyclically during the second-half cycle) and LNG-IUS.*
- *During medical treatment, follow-up and efficacy evaluation should be conducted, with TVS re-examination recommended up to 6 months depending on the presence of clinical symptoms and/or risk factors.*
- *Treatment regimens should be adjusted based on evaluation results and patient compliance*

Surgical management

Q1: Which conditions of endometrial polyps require surgery?

Firstly, it is generally agreed that symptomatic endometrial polyps (such as abnormal uterine bleeding and postmenopausal bleeding) are an indication for surgery (4).

The second surgical indication is related to the fertility setting. The correlation between hysteroscopic polypectomy and clinical benefits in the fertile population has been deeply investigated (16,76–78). The strongest evidence comes from a prospective randomised trial in infertile patients with endometrial polyps undergoing intrauterine insemination (IUI), which showed that preoperative hysteroscopic polypectomy before IUI doubled the clinical pregnancy rate (16). For patients undergoing IVF treatment, several systematic reviews have reported that routine hysteroscopy to assess the uterine cavity and treat polyps before IVF is associated with higher clinical pregnancy and live birth rates (11,67,79). In cases of patients undergoing IVF/ICSI, polypectomy should not be performed in the cycle of embryo transfer but in a previous cycle to allow recovery of the endometrium (80).

The third situation for considering surgery is in certain special cases of asymptomatic polyps in premenopausal or postmenopausal women. For asymptomatic patients in the perimenopausal or postmenopausal period, if endometrial polyps are detected, regardless of the size of the polyps, a detailed hysteroscopy examination is required, and polyp removal surgery must be performed. At the same time, it is recommended to undergo endometrial curettage to rule out subclinical endometrial hyperplasia or canceration (60). Finally, if asymptomatic polyps are associated with high-risk precancerous or malignant lesions, a hysteroscopy examination should be conducted immediately, and tissue biopsy should be performed for pathological diagnosis (81).

Key points

- *Hysteroscopic removal of endometrial polyps remains the gold standard procedure.*
- *Endometrial polyps with typical clinical symptoms, such as abnormal uterine bleeding, require surgical treatment.*
- *Endometrial polyps persistent after medical therapy require surgical treatment to confirm histology.*
- *Hysteroscopic treatment might be applied in patients with infertility or medically assisted reproduction; polypectomy in ART patients should be performed in a previous cycle of embryo transfer or IUI.*
- *Those with high risk factors for suspected malignancy, polypectomy and endometrial curettage should be performed at the same time.*

Table 1: The effect of endometrial polyps and benefits of polypectomy

Symptom / Condition	Effect of Endometrial polyps	Evidence of polypectomy
Abnormal Uterine Bleeding	Strong association	Strong clinical rationale
Natural conception	Possible adverse effect	May improve pregnancy; no definitive RCT evidence
Infertility	Plausible association	Benefit likely but heterogeneous evidence
Intrauterine Insemination	Important reproductive relevance	Good evidence of benefit
IVF/ICSI	Possible effect on implantation	Benefit remains uncertain, especially for small asymptomatic polyps

Miscarriage	Possible association	No convincing evidence of reduction

Q2: Does hysteroscopic resection of endometrial polyps increase the risk of malignant cell dissemination?

Concern has been raised that hysteroscopic procedures performed in women with occult atypical hyperplasia or endometrial carcinoma may facilitate dissemination of malignant cells through the fallopian tubes into the peritoneal cavity.

A retrospective multicentre study enrolled 1,731 patients with endometrial cancer and compared outcomes between patients who underwent preoperative hysteroscopy and those receiving blind Pipelle biopsy. After 10 years of follow-up, no significant differences were observed between the two groups in terms of recurrence rate, disease-free survival, and overall survival (82). A multicentre study conducted by Namazov et al. enrolled 1324 patients with stage I endometrial carcinoma. The findings confirmed that hysteroscopy does not compromise the survival of patients with early-stage endometrial cancer (83), Du et al. demonstrated no significant correlation between hysteroscopy and adverse prognosis in early endometrial cancer; the 5-year disease-free survival showed no difference between patients with and without hysteroscopy (84). The 2023 guidelines issued by the European Society of Gynaecological Oncology (ESGO) clearly state that potential tumour cell dissemination has not been proven to alter tumour staging or exert an adverse impact on patient prognosis (85). When malignancy is suspected, excessive intrauterine distension pressure should be avoided to minimise potential transtubal dissemination of endometrial cells (86).

Key points

- *The risk of malignant tumour cell dissemination caused by hysteroscopic resection of endometrial polyps is extremely low and similar to D&C.*
- *Current evidence also indicates that even if minimal tumour cell dissemination occurs, it has not worsened tumour staging or impaired patient prognosis compared to D&C.*
- *Hysteroscopy should not be withheld when clinically indicated, solely because of theoretical concerns regarding tumour dissemination.*

Q3: What is the surgical management of endometrial adenomyomatous polyps (polypoid adenomyomas)?

Endometrial adenomyomatous polyp, also known as endometrial polypoid adenomyoma, is an extremely rare polypoid uterine neoplasm. It is composed of smooth muscle stroma and endometrial glands. Its histological origin and pathogenesis remain unclear (87,88). According to

whether there is typical hyperplasia in the glands, it can be classified into typical polypoid adenomyoma (TPA) and atypical polypoid adenomyoma (APA) (89). In the hysteroscopic images, adenomyomatous polyps are very similar to traditional endometrial polyps and submucosal intracavitary fibromas. Atypical polypoid adenomyoma is a lesion of undetermined malignant potential, and its morphology can be similar to atypical endometrial hyperplasia (90,91). A large sample size case-control study showed that the proportion of endometrial adenomyomatous polyps was increased in postmenopausal women, and the recurrence rate after hysteroscopic surgery was higher in postmenopausal women than in premenopausal women. Therefore, attention should be paid to the identification and management of this disease in postmenopausal women in clinical practice (87). For patients with fertility needs, who wish to reduce the risk of recurrence and improve the diagnostic accuracy of concurrent endometrial cancer, it is recommended to adopt conservative treatment with hysteroscopic surgery and conduct regular close follow-up. The four-steps hysteroscopic technique for atypical polypoid adenomyomas described by Di Spiezio Sardo et al. involves margin-controlled resection of the polyp for histopathology, excision of perilesional endometrium, resection of underlying myometrium, and multiple random endometrial biopsies (92). Patients in the perimenopausal and postmenopausal stages are suitable for hysterectomy (90).

Key points

- *Hysteroscopic excision is recommended for adenomyomatous/polyploid adenomyomatous lesions. According to their pathogenesis and pathological characteristics, extending the resection depth and random endometrial biopsies are needed and might prevent their recurrence.*
- *Atypical forms need special attention due to their malignant potential and co-existence with atypical hyperplasia and endometrial cancer.*

Prevention

Key question

Q1 How to prevent postoperative recurrence of endometrial polyps?

The recurrence of endometrial polyps with high-risk characteristics include obesity, PCOS, metabolic syndrome (hypertension, diabetes), and tamoxifen use. Obesity, polycystic ovary syndrome, insulin resistance, diabetes and hypertension are well established independent risk factors for postoperative polyp recurrence. Weight control, management of hypertension, diabetes, and PCOS, as well as avoidance of prolonged unopposed estrogen exposure, constitute fundamental preventive measures post endometrial polyp surgery. Lifestyle modification and metabolic risk factor intervention should be the cornerstone of long-term postoperative management (93).

Immediate placement of the levonorgestrel intrauterine sustained release system (LNG-IUS) during polypectomy serves as first-line prevention, significantly reducing recurrence rates, particularly in patients with multiple polyps or abnormal bleeding. Studies demonstrate that postoperative LNG-IUS placement markedly reduces polyp recurrence rates (RR=0.218). A 2024 systematic meta-analysis reported postoperative recurrence rates of 2.38% to 5.17% in LNG-IUS users versus 13.55% to 35.0% in untreated controls, identifying LNG-IUS as an independent protective factor regardless of age, polyp size or surgical history (75). Compared to oral progestins or combined oral contraceptives (COCs), LNG-IUS offers distinct advantages: lower recurrence rates, fewer systemic adverse reactions, and higher patient compliance (with a single placement providing efficacy for 5 years). Intraoperative immediate placement under hysteroscopic vision can avoid secondary surgical trauma and guarantee accurate device positioning (94).

For individuals who temporarily have no fertility needs and demonstrate good medication adherence, combined oral contraceptives (COCs) may also be considered. However, patients initiating COCs use after the age of 40 require thrombotic risk assessment. COCs are a protective factor against endometrial polyps and can reduce both their occurrence and recurrence. Combined use of COCs for 3–6 months after hysteroscopic transcervical resection of endometrial polyps (TCRP) not only helps decrease postoperative bleeding and regulate the menstrual cycle, but also significantly controls polyp recurrence (94).

Periodic oral administration of dydrogesterone significantly reduces recurrence rates and improves bleeding symptoms, making it suitable for individuals with recent fertility needs. Compared with LNG-IUS, oral dydrogesterone yields higher postoperative recurrence rates in real world cohorts but preserves ovarian function and fertility potential (95).

Key points

- Prevention of recurrence should focus on long-term management of underlying causes and risk factors such as obesity, insulin resistance and PCOS.
- Hysteroscopic endometrial polypectomy followed by LNG-IUS placement is an effective strategy for recurrence prevention in patients without recent fertility desire; immediate placement of the LNG-IUS might be an option to lower re-intervention burden.

References

1. Salim S, Won H, Nesbitt-Hawes E, Campbell N, Abbott J. Diagnosis and Management of Endometrial Polyps: A Critical Review of the Literature. J Minim Invasive Gynecol. 2011 Sep;18(5):569–81. doi:10.1016/j.jmig.2011.05.018

2. Nijkang NP, Anderson L, Markham R, Manconi F. Endometrial polyps: Pathogenesis, sequelae and treatment. SAGE Open Med. 2019;7:2050312119848247. doi:10.1177/2050312119848247 PubMed PMID: 31105939.
3. AAGL Practice Report: Practice Guidelines for the Diagnosis and Management of Endometrial Polyps. J Minim Invasive Gynecol. 2012 Jan;19(1):3–10. doi:10.1016/j.jmig.2011.09.003
4. Bougie O, Randle E, Thurston J, Magee B, Warshafsky C, Rittenberg D. Guideline No. 447: Diagnosis and Management of Endometrial Polyps. Journal of Obstetrics and Gynaecology Canada. 2024 Mar;46(3):102402. doi:10.1016/j.jogc.2024.102402
5. Vitale SG, Haimovich S, Laganà AS, Alonso L, Di Spiezio Sardo A, Carugno J. Endometrial polyps. An evidence-based diagnosis and management guide. European Journal of Obstetrics & Gynecology and Reproductive Biology. 2021 May;260:70–7. doi:10.1016/j.ejogrb.2021.03.017
6. Al-Rayes S, Mohamed M, Suarthana E, Kigloo HN, Raina J, Tulandi T. Risks of Malignancy among 11,204 Patients with Endometrial Polyp: A Systematic Review and Meta-analysis. Gynecol Minim Invasive Ther. 2025 Jan;14(1):40–50. doi:10.4103/gmit.GMIT-D-24-00056
7. Sanin-Ramirez D, Carriles I, Graupera B, Ajossa S, Neri M, Rodriguez I, et al. Two-dimensional transvaginal sonography *vs* saline contrast sonohysterography for diagnosing endometrial polyps: systematic review and meta-analysis. Ultrasound in Obstetrics & Gynecology. 2020 Oct 14;56(4):506–15. doi:10.1002/uog.22161
8. Devine K, Dolitsky S, Ludwin I, Ludwin A. Modern assessment of the uterine cavity and fallopian tubes in the era of high-efficacy assisted reproductive technology. Fertil Steril. 2022 Jul;118(1):19–28. doi:10.1016/j.fertnstert.2022.05.020
9. Bettocchi S, Nappi L, Ceci O, Selvaggi L. What does ‘diagnostic hysteroscopy’ mean today? The role of the new techniques. Curr Opin Obstet Gynecol. 2003 Aug;15(4):303–8. doi:10.1097/01.gco.0000084241.09900.c8
10. Saleem Z. Association of endometrial pathologies with infertility and malignant potential in pre- and postmenopausal women—a systematic review. British Journal of Radiology. 2026 May 1;99(1181):859–65. doi:10.1093/bjr/tqag031
11. Howells P, Vigneswaran K, Sarris I, Melo P, Bhandari H, Subramanian V. Management of endometrial polyps in fertility: British fertility Society policy and practice guideline. Hum Fertil. 2026 Dec 31;29(1). doi:10.1080/14647273.2026.2633925
12. Jee BC, Jeong HG. Management of endometrial polyps in infertile women: A mini-review. Clin Exp Reprod Med. 2021 Sep 1;48(3):198–202. doi:10.5653/cerm.2020.04119
13. DeWaay D. Natural history of uterine polyps and leiomyomata. Obstetrics & Gynecology. 2002 Jul;100(1):3–7. doi:10.1016/S0029-7844(02)02007-0

14. Hou JH, Lu BJ, Huang YL, Chen CH, Chen CH. Outpatient hysteroscopy impact on subsequent assisted reproductive technology: a systematic review and meta-analysis in patients with normal transvaginal sonography or hysterosalpingography images. Reproductive Biology and Endocrinology. 2024 Feb 1;22(1):18. doi:10.1186/s12958-024-01191-0
15. Schutyser V, Agius MP, Drakopoulos P, van Landuyt L, De Vos M, Tournaye H, et al. Managing suspected endometrial polyps during IVF/ICSI stimulation: retrospective cohort study of fresh versus freeze-all strategies. Reprod Biomed Online. 2026 Jul;53(1):105357. doi:10.1016/j.rbmo.2025.105357
16. Pérez-Medina T, Bajo-Arenas J, Salazar F, Redondo T, Sanfrutos L, Alvarez P, et al. Endometrial polyps and their implication in the pregnancy rates of patients undergoing intrauterine insemination: a prospective, randomized study. Human Reproduction. 2005 Jun 1;20(6):1632–5. doi:10.1093/humrep/deh822
17. Gracia C, Amato P, Flyckt R, Ginsburg E, Brannigan R, Sakkas D, et al. Recurrent implantation failure: a committee opinion. Fertil Steril. 2026 Aug;126(2):277–93. doi:10.1016/j.fertnstert.2026.03.026
18. Busnelli A, Barbaro G, Pozzati F, D'Ippolito S, Cristodoro M, Nobili E, et al. The importance of the 'uterine factor' in recurrent pregnancy loss: a retrospective cohort study on women screened through 3D transvaginal ultrasound. Human Reproduction. 2024 Aug 1;39(8):1645–55. doi:10.1093/humrep/deae148
19. Uglietti A, Buggio L, Farella M, Chiaffarino F, Dridi D, Vercellini P, et al. The risk of malignancy in uterine polyps: A systematic review and meta-analysis. European Journal of Obstetrics & Gynecology and Reproductive Biology. 2019 Jun;237:48–56. doi:10.1016/j.ejogrb.2019.04.009
20. Visually directed hysteroscopic biopsy in the evaluation of abnormal uterine bleeding and postmenopausal bleeding: a Joint Society Practice Guideline. Facts Views Vis Obgyn. 2026 Jul 29. doi:10.52054/FVVO.2026.514
21. van Gemert J, Herman MC, Beelen P, Geomini PM, Bongers MY. Endometrial polypectomy using tissue removal device or electrosurgical snare: a randomised controlled trial. Facts Views Vis Obgyn. 2022 Sep;14(3):235–43. doi:10.52054/FVVO.14.3.035 PubMed PMID: 36206798.
22. Hui P. Endometrial Polyp in Postmenopausal Women: An Epicenter for the Development of Endometrial Serous Carcinoma. Arch Pathol Lab Med. 2023 Apr 1;147(4):413–7. doi:10.5858/arpa.2021-0557-RA
23. Jones ER, O'Flynn H, Njoku K, Crosbie EJ. Detecting endometrial cancer. The Obstetrician & Gynaecologist. 2021 Apr 27;23(2):103–12. doi:10.1111/tog.12722

24. Lee SC, Kaunitz AM, Sanchez-Ramos L, Rhatigan RM. The Oncogenic Potential of Endometrial Polyps. Obstetrics & Gynecology. 2010 Nov;116(5):1197–205. doi:10.1097/AOG.0b013e3181f74864
25. Sasaki LMP, Andrade KRC, Figueiredo ACMG, Wanderley M da S, Pereira MG. Factors Associated with Malignancy in Hysteroscopically Resected Endometrial Polyps: A Systematic Review and Meta-Analysis. J Minim Invasive Gynecol. 2018 Jul;25(5):777–85. doi:10.1016/j.jmig.2018.02.004
26. McGowan MA, Davies JM, Addley S, Honeyman LJ, Kolhe SN, Phillips AJ. Does the presence of single compared to multiple endometrial polyps alter the risk of cancer in post-menopausal women? European Journal of Obstetrics & Gynecology and Reproductive Biology. 2022 Dec;279:118–21. doi:10.1016/j.ejogrb.2022.10.018
27. Garuti G, Luerti M, Leone F, Perrini G, DeaLberti D, ViteLLi V, et al. Prevalence and predictors of atypical histology in endometrial polyps removed by hysteroscopy: A secondary analysis from the SICMIG hysteroscopy trial hySteroSCoPiStS GrouP. Vol. 15.
28. Eubanks AA, Consoli RJ, Langston A. Endometrial Polyp. 2026. PubMed PMID: 32491756.
29. Serhat E, Cogendez E, Selcuk S, Asoglu MR, Arioglu PF, Eren S. Is there a relationship between endometrial polyps and obesity, diabetes mellitus, hypertension? Arch Gynecol Obstet. 2014 Nov 24;290(5):937–41. doi:10.1007/s00404-014-3279-4
30. Hsu C, Eing-Mei T, Hui-min H. P-317 Risk of endometrial polyps and hyperplasia after tamoxifen treatment in women with breast cancer: a population-based study in Taiwan. Human Reproduction. 2024 Jul 3;39(Supplement_1). doi:10.1093/humrep/deae108.682
31. Keyif B, Yavuzcan A, Yurtçu E, Başbuğ A, Düzenli F, Keyif E, et al. Exploring the Inflammatory Basis of Endometrial Polyps: Clinical Implications of Hematological Biomarkers in a Retrospective Study. J Clin Med. 2025 Apr 17;14(8):2754. doi:10.3390/jcm14082754
32. El-Hamarneh T, Hey-Cunningham AJ, Berbic M, Al-Jefout M, Fraser IS, Black K. Cellular immune environment in endometrial polyps. Fertil Steril. 2013 Nov;100(5):1364–72. doi:10.1016/j.fertnstert.2013.06.050
33. Fiore A, Casalechi M, Somigliana E, Viganò P, Salmeri N. Association between endometriosis and endometrial polyps: a systematic review and meta-analysis. Reprod Biomed Online. 2026 Jan;52(1):105106. doi:10.1016/j.rbmo.2025.105106
34. Weigel GM, Baison GN, Mihalov L, Mupombwa T. Prevalence of and risk factors for endometrial polyps among asymptomatic postmenopausal women with uterovaginal prolapse. Am J Obstet Gynecol. 2025 Feb;232(2):196.e1-196.e6. doi:10.1016/j.ajog.2024.08.001

35. Ricciardi E, Vecchione A, Marci R, Schimberni M, Frega A, Maniglio P, et al. Clinical factors and malignancy in endometrial polyps. Analysis of 1027 cases. European Journal of Obstetrics & Gynecology and Reproductive Biology. 2014 Dec;183:121–4. doi:10.1016/j.ejogrb.2014.10.021
36. Jang S, Hwang SO. The risk factors for premalignant and malignant endometrial polyps in premenopausal and postmenopausal women and trends over the past decade: A retrospective study in a single center, South Korea. European Journal of Obstetrics & Gynecology and Reproductive Biology. 2024 Apr;295:118–23. doi:10.1016/j.ejogrb.2024.01.033
37. Costa-Paiva L, Godoy CE, Antunes A, Caseiro JD, Arthuso M, Pinto-Neto AM. Risk of malignancy in endometrial polyps in premenopausal and postmenopausal women according to clinicopathologic characteristics. Menopause. 2011 Dec;18(12):1278–82. doi:10.1097/gme.0b013e31821e23a1
38. Wong M, Thanatsis N, Nardelli F, Amin T, Jurkovic D. Risk of Pre-Malignancy or Malignancy in Postmenopausal Endometrial Polyps: A CHAID Decision Tree Analysis. Diagnostics. 2021 Jun 15;11(6):1094. doi:10.3390/diagnostics11061094
39. Karakas LA, Atilgan AO, Akilli H, Kuscu UE, Haberal A, Ayhan A. Nulliparity and postmenopausal status are independent factors of malignancy potential of endometrial intraepithelial neoplasia in polyps. International Journal of Gynecology & Obstetrics. 2021 Mar 15;152(3):433–8. doi:10.1002/ijgo.13448
40. Lu L, Luo J, Deng J, Huang C, Li C. Polycystic ovary syndrome is associated with a higher risk of premalignant and malignant endometrial polyps in premenopausal women: a retrospective study in a tertiary teaching hospital. BMC Womens Health. 2023 Mar 24;23(1):127. doi:10.1186/s12905-023-02269-4
41. Kilicdag EB, Haydardedeoglu B, Cok T, Parlakgumus AH, Simsek E, Bolat FA. Polycystic ovary syndrome and increased polyp numbers as risk factors for malignant transformation of endometrial polyps in premenopausal women. International Journal of Gynecology & Obstetrics. 2011 Mar 17;112(3):200–3. doi:10.1016/j.ijgo.2010.10.014
42. Noah N, Gilani M, Kumar R. Asymptomatic endometrial cancer with Lynch syndrome; in a woman with primary infertility—A case report and literature review. International Journal of Gynecology & Obstetrics. 2024 Oct 2;167(1):58–61. doi:10.1002/ijgo.15578
43. Ryan NAJ, Blake D, Cabrera-Dandy M, Glaire MA, Evans DG, Crosbie EJ. The prevalence of Lynch syndrome in women with endometrial cancer: a systematic review protocol. Syst Rev. 2018 Aug 16;7(1):121. doi:10.1186/s13643-018-0792-8 PubMed PMID: 30115102.
44. Van Den Bosch T, Verbakel JY, Valentin L, Wynants L, De Cock B, Pascual MA, et al. Typical ultrasound features of various endometrial pathologies described using International Endometrial

Tumor Analysis (<scp>IETA</scp>) terminology in women with abnormal uterine bleeding. Ultrasound in Obstetrics & Gynecology. 2021 Jan 2;57(1):164–72. doi:10.1002/uog.22109

45. Heremans R, Van den Bosch T, Valentin L, Wynants L, Pascual MA, Fruscio R, et al. Ultrasound features of endometrial pathology in women without abnormal uterine bleeding: results from the International Endometrial Tumor Analysis study (<scp>IETA3</scp>). Ultrasound in Obstetrics & Gynecology. 2022 Aug;60(2):243–55. doi:10.1002/uog.24910
46. Van den Bosch T, Heremans R, Landolfo C, Epstein E, Leone FPG, Bourne T, et al. <scp>ISUOG Consensus Statement</scp> on sonographic assessment of the endometrium: how to perform a gynecological ultrasound scan and report the findings. Ultrasound in Obstetrics & Gynecology. 2026 Feb 16;67(2):241–58. doi:10.1002/uog.70163
47. Heremans R, Wynants L, Valentin L, Leone FPG, Pascual MA, Fruscio R, et al. Estimating risk of endometrial malignancy and other intracavitary uterine pathology in women without abnormal uterine bleeding using <scp>IETA</scp> -1 multinomial regression model: validation study. Ultrasound in Obstetrics & Gynecology. 2024 Apr 4;63(4):556–63. doi:10.1002/uog.27530
48. Kaveh M, Sadegi K, Salarzaei M, Parooei F. Comparison of diagnostic accuracy of saline infusion sonohysterography, transvaginal sonography, and hysteroscopy in evaluating the endometrial polyps in women with abnormal uterine bleeding: a systematic review and meta-analysis. Wideochir Inne Tech Maloinwazyjne. 2020 Sep;15(3):403–15. doi:10.5114/wiitm.2020.93791 PubMed PMID: 32904526.
49. Marcone D, Zupi E, Valli E, Felice M Di, Solima E, Romanini C. Hysteroscopic appearance of benign and malignant endometrial polyps. What are the differences? J Am Assoc Gynecol Laparosc. 1994 Aug;1(4):S21. doi:10.1016/S1074-3804(05)80934-X
50. Ngo YG, Fu HC, Chu LC, Tseng CW, Chen CY, Lee CY, et al. Specific hysteroscopic findings can efficiently distinguish the differences between malignant and benign endometrial polyps. Taiwan J Obstet Gynecol. 2020 Jan;59(1):85–90. doi:10.1016/j.tjog.2019.11.013
51. Shor S, Pansky M, Maymon R, Vaknin Z, Smorgick N. Prediction of Premalignant and Malignant Endometrial Polyps by Clinical and Hysteroscopic Features. J Minim Invasive Gynecol. 2019 Nov;26(7):1311–5. doi:10.1016/j.jmig.2018.12.018
52. Vitale SG, Buzzaccarini G, Riemma G, Pacheco LA, Di Spiezio Sardo A, Carugno J, et al. Endometrial biopsy: Indications, techniques and recommendations. An evidence-based guideline for clinical practice. J Gynecol Obstet Hum Reprod. 2023 Jun;52(6):102588. doi:10.1016/j.jogoh.2023.102588
53. Di Spiezio Sardo A, Saccone G, Carugno J, Pacheco LA, Zizolfi B, Haimovich S, et al. Endometrial biopsy under direct hysteroscopic visualisation versus blind endometrial sampling for the diagnosis

of endometrial hyperplasia and cancer: Systematic review and meta-analysis. Facts Views Vis Obgyn. 2022 Jun 30;14(2):103–10. doi:10.52054/FVVO.14.2.023

54. Kim KR, Peng R, Ro JY, Robboy SJ. A Diagnostically Useful Histopathologic Feature of Endometrial Polyp. American Journal of Surgical Pathology. 2004 Aug;28(8):1057–62. doi:10.1097/01.pas.0000128659.73944.f3
55. Nogueira AA, Reis FJC Dos, Silva JCRE, Netto OBP, Barbosa H de F. Endometrial Polyps: A Review. J Gynecol Surg. 2007 Sep;23(3):111–6. doi:10.1089/gyn.2006.B-02256-2
56. Travaglino A, Raffone A, Saccone G, Fuggi M, De Placido G, Mascolo M, et al. Immunophenotype of Atypical Polypoid Adenomyoma of the Uterus: Diagnostic Value and Insight on Pathogenesis. Applied Immunohistochemistry & Molecular Morphology. 2020 Sep;28(8):646–53. doi:10.1097/PAI.0000000000000780
57. Sheng KK, Lyons SD. To treat or not to treat? An evidence-based practice guide for the management of endometrial polyps. Climacteric. 2020 Jul 3;23(4):336–42. doi:10.1080/13697137.2020.1742107
58. Han MN, Munro MG. Endometrial Polyps. Obstetrics & Gynecology. 2026 Oct;148(4):489–507. doi:10.1097/AOG.0000000000006232
59. Raz N, Feinmesser L, Moore O, Haimovich S. Endometrial polyps: diagnosis and treatment options – a review of literature. Minimally Invasive Therapy & Allied Technologies. 2021 Oct 1;30(5):278–87. doi:10.1080/13645706.2021.1948867
60. Tanos V, Berry KE, Seikkula J, Abi Raad E, Stavroulis A, Sleiman Z, et al. The management of polyps in female reproductive organs. International Journal of Surgery. 2017 Jul;43:7–16. doi:10.1016/j.ijsu.2017.05.012
61. Yuksel S, Tuna G, Celik HG, Salman S. Endometrial polyps: Is the prediction of spontaneous regression possible? Obstet Gynecol Sci. 2021 Jan 15;64(1):114–21. doi:10.5468/ogs.20242
62. Mak KS, Huang YT, Su YY, Pan YB, Lin YS, Weng CH, et al. Clinical outcomes in women with endometrial polyps underwent conservative management. Taiwan J Obstet Gynecol. 2023 Jul;62(4):553–8. doi:10.1016/j.tjog.2022.08.022
63. Silva AR, Santos M, Coelho A, Condeço R, Alpendre F, Ambrósio P, et al. Expectant management as a primary approach for asymptomatic endometrial polyps: An ambispective cohort study. European Journal of Obstetrics & Gynecology and Reproductive Biology. 2026 Mar;319:114986. doi:10.1016/j.ejogrb.2026.114986
64. Afifi K, Anand S, Nallapeta S, Gelbaya TA. Management of endometrial polyps in subfertile women: a systematic review. European Journal of Obstetrics & Gynecology and Reproductive Biology. 2010 Aug;151(2):117–21. doi:10.1016/j.ejogrb.2010.04.005

65. Pereira N, Petrini AC, Lekovich JP, Elias RT, Spandorfer SD. Surgical Management of Endometrial Polyps in Infertile Women: A Comprehensive Review. Surg Res Pract. 2015;2015:1–7. doi:10.1155/2015/914390
66. Humphries LA, Traub AM, Shah DK. Surgical interventions to optimize fertility. Fertil Steril. 2026 Jun;125(6):973–82. doi:10.1016/j.fertnstert.2026.02.003
67. Goc G, Birge O. Endometrial Polyps and Subfertility in Women Under 40: Pathophysiology, Fertility Outcomes, and Clinical Management. Medicina (B Aires). 2026 Apr 3;62(4):692. doi:10.3390/medicina62040692
68. Jayaprakasan K, Polanski L, Sahu B, Thornton JG, Raine-Fenning N. Surgical intervention versus expectant management for endometrial polyps in subfertile women. Cochrane Database of Systematic Reviews. 2014 Aug 30;2021(2). doi:10.1002/14651858.CD009592.pub2
69. Timmermans A, Veersema S, van Kerkvoorde T, van der Voet L, Opmeer B, Bongers M, et al. Should endometrial polyps be removed in patients with postmenopausal bleeding?—an assessment of study designs and report of a failed randomised controlled trial (ISRCTN73825127). BJOG. 2009 Sep 10;116(10):1391–5. doi:10.1111/j.1471-0528.2009.02234.x
70. Wolfman W, Bougie O, Chen I, Tang Y, Goldstein S, Bouteaud J. Guideline No. 451: Asymptomatic Endometrial Thickening in Postmenopausal Women. Journal of Obstetrics and Gynaecology Canada. 2024 Jul;46(7):102591. doi:10.1016/j.jogc.2024.102591
71. de Rijk SR, Steenbergen ME, Nieboer TE, Coppus SF. Atypical Endometrial Polyps and Concurrent Endometrial Cancer. Obstetrics & Gynecology. 2016 Sep;128(3):519–25. doi:10.1097/AOG.0000000000001566
72. Committee Opinion No. 601. Obstetrics & Gynecology. 2014 Jun;123(6):1394–7. doi:10.1097/01.AOG.0000450757.18294.cf
73. Buijs C, Willemse PHB, de Vries EGE, Ten Hoor KA, Boezen HM, Hollema H, et al. Effect of Tamoxifen on the Endometrium and the Menstrual Cycle of Premenopausal Breast Cancer Patients. International Journal of Gynecological Cancer. 2009 Apr;19(4):677–81. doi:10.1111/IGC.0b013e3181a47cbe
74. Saccardi C, Gizzo S, Patrelli TS, Ancona E, Anis O, Di Gangi S, et al. Endometrial surveillance in tamoxifen users: role, timing and accuracy of hysteroscopic investigation: observational longitudinal cohort study. Endocr Relat Cancer. 2013 Aug;20(4):455–62. doi:10.1530/ERC-13-0020
75. Luo A, Shen W, Lv X, Yang S. Endometrial polyps recurrence: risk factors, prevention, and management. Open Medicine. 2026 Jan 23;21(1). doi:10.1515/med-2026-1417

76. Zhang L, Han Q, Bao MR, Wu Y. Impact of Endometrial Polyps on Pregnancy Outcomes in Patients with Endometriosis and Infertility: A Systematic Review and Meta-analysis. Biomed Environ Sci. 2025 Mar 20;38(3):341–50. doi:10.3967/bes2024.175 PubMed PMID: 40237269.
77. Rackow BW, Jorgensen E, Taylor HS. Endometrial polyps affect uterine receptivity. Fertil Steril. 2011 Jun;95(8):2690–2. doi:10.1016/j.fertnstert.2010.12.034
78. Vaduva CC, Constantinescu C, Serbanescu M, Dara L, Oancea MD, Carp-Veliscu A. The association between endometrial polyps, chronic endometritis, and IVF outcomes. Eur Rev Med Pharmacol Sci. 2023 Sep;27(18):8895–904. doi:10.26355/eurrev_202309_33810 PubMed PMID: 37782198.
79. Di Spiezio Sardo A, Di Carlo C, Minozzi S, Spinelli M, Pistotti V, Alviggi C, et al. Efficacy of hysteroscopy in improving reproductive outcomes of infertile couples: a systematic review and meta-analysis. Hum Reprod Update. 2016 Jun;22(4):479–96. doi:10.1093/humupd/dmw008
80. Ghaffari F, Arabipoor A, Bagheri Lankarani N, Hosseini F, Bahmanabadi A. Hysteroscopic polypectomy without cycle cancellation in IVF/ICSI cycles: a cross-sectional study. European Journal of Obstetrics & Gynecology and Reproductive Biology. 2016 Oct;205:37–42. doi:10.1016/j.ejogrb.2016.08.019
81. Ludwin A, Lindheim SR, Booth R, Ludwin I. Removal of uterine polyps: clinical management and surgical approach. Climacteric. 2020 Jul 3;23(4):388–96. doi:10.1080/13697137.2020.1784870
82. Quintana-Bertó R, Padilla-Iserte P, Gil-Moreno A, Oliver-Pérez R, Coronado PJ, Martín-Salamanca MB, et al. Oncological safety of hysteroscopy in endometrial cancer. International Journal of Gynecological Cancer. 2022 Nov;32(11):1395–401. doi:10.1136/ijgc-2022-003586
83. Namazov A, Gemer O, Helpman L, Hag-Yahia N, Eitan R, Raban O, et al. The oncological safety of hysteroscopy in the diagnosis of early-stage endometrial cancer: An Israel gynecologic oncology group study. European Journal of Obstetrics & Gynecology and Reproductive Biology. 2019 Dec;243:120–4. doi:10.1016/j.ejogrb.2019.10.042
84. Du Y, Xu Y, Qin Z, Sun L, Chen Y, Han L, et al. The Oncology Safety of Diagnostic Hysteroscopy in Early-Stage Endometrial Cancer: A Systematic Review and Meta-Analysis. Front Oncol. 2021 Oct 21;11. doi:10.3389/fonc.2021.742761
85. Rodolakis A, Scambia G, Planchamp F, Acien M, Di Spiezio Sardo A, Farrugia M, et al. ESGO/ESHRE/ESGE Guidelines for the fertility-sparing treatment of patients with endometrial carcinoma,. Hum Reprod Open. 2022 Dec 13;2023(1). doi:10.1093/hropen/hoac057
86. Yang B, Xu Y, Zhu Q, Xie L, Shan W, Ning C, et al. Treatment efficiency of comprehensive hysteroscopic evaluation and lesion resection combined with progestin therapy in young women

with endometrial atypical hyperplasia and endometrial cancer. Gynecol Oncol. 2019 Apr;153(1):55–62. doi:10.1016/j.ygyno.2019.01.014

87. Wang X, Zhang H, Xu J, Qu P. The typical polypoid adenomyoma is a special form of endometrial polyp: a case-controlled study with a large sample size. Eur J Med Res. 2023 Aug 30;28(1):308. doi:10.1186/s40001-023-01286-1 PubMed PMID: 37649048.
88. Li J, Li B, He J, Ouyang L. Gonadotropin-releasing hormone analog (GnRHa) combined with hysteroscopic surgery in the treatment of giant endometrial adenomyomatous polyps: A case report. Asian J Surg. 2023 Oct;46(10):4608–9. doi:10.1016/j.asjsur.2023.05.041
89. McCluggage WG. A practical approach to the diagnosis of mixed epithelial and mesenchymal tumours of the uterus. Modern Pathology. 2016;29:S78–91. doi:10.1038/modpathol.2015.137
90. Biasioli A, Londero AP, Orsaria M, Scrimin F, Mangino FP, Bertozzi S, et al. Atypical polypoid adenomyoma follow-up and management: Systematic review of case reports and series and meta-analysis. Medicine. 2020 Jun 26;99(26):e20491. doi:10.1097/MD.0000000000020491 PubMed PMID: 32590732.
91. Mikos T, Tsolakidis D, Grimbizis GF. Clinical presentation and management of atypical polypoid adenomyomas: Systematic review of the literature. European Journal of Obstetrics & Gynecology and Reproductive Biology. 2019 May;236:14–21. doi:10.1016/j.ejogrb.2019.02.027
92. Di Spiezio Sardo A, Mazzon I, Gargano V, Di Carlo C, Guida M, Mignogna C, et al. Hysteroscopic treatment of atypical polypoid adenomyoma diagnosed incidentally in a young infertile woman. Fertil Steril. 2008 Feb;89(2):456.e9-456.e12. doi:10.1016/j.fertnstert.2007.02.061
93. Rshoud F, Omari B, Qudsi A, Salhiyeh A. Polycystic ovarian syndrome – association and risk factors between endometrial polyp and infertility. A retrospective study. Menopausal Review. 2022;21(2):106–10. doi:10.5114/pm.2022.116478
94. Li L, Zhu L. Chinese guidelines on the management of endometrial hyperplasia. European Journal of Surgical Oncology. 2024 Jul;50(7):108391. doi:10.1016/j.ejso.2024.108391
95. Jiang Y, Li X, Wu J, Jiang C, Yang Y, Wei H. The efficacy of levonorgestrelintrauterine system, drospirenone & ethinylestradiol tablets (II) and dydrogesterone in preventing the recurrence of endometrial polyps. Arch Gynecol Obstet. 2024 Jul 1;310(3):1645–9. doi:10.1007/s00404-024-07605-z